

Acute Tetraethyllead Poisoning

M. STASIK, Z. BYCZKOWSKA, S. SZENDZIKOWSKI, and Z. FIEDORCZUK

Clinical and Pathomorphological Department,
Institute of Occupational Medicine, Łódź, Poland,
Department of Forensic Medicine, Medical Academy, Łódź

Received September 16, 1968

Summary. Four cases of accidental poisoning with tetraethyllead are described. Three out of four of the patients died.

In the first case, pure ethyl fluid was accidentally ingested. Dominating the clinical picture of this patient were signs of greatly elevated intracranial pressure. Three other persons were poisoned as a group. They unknowingly inhaled tetraethyllead contained in a paint solvent they used. In these three cases, the intoxication manifested itself predominantly as a mental disorder suggestive of schizophrenia.

Gross and microscopic changes observed in the fatal cases gave evidence of a capillary vascular lesion, particularly involving the vessels of the CNS. Liver damage and less severe damage to the heart muscle and kidney parenchyma were also noted.

The distribution as well as the extent of the above mentioned lesions correlate approximately with the distribution and concentration of triethyllead in the various internal organs.

Key-Words: Tetraethyllead — Mental Disorder — Damage to Parenchymatous Organs.

Zusammenfassung. Die Verfasser berichten über 4 Fälle, von denen 3 tödlich waren, zufälliger Vergiftungen durch das sog. Ethylfluid, das Bleitetraäthyl enthält.

Im ersten Fall trat die tödliche Vergiftung infolge irrtümlich getrunkenem Ethylfluid auf. Als klinisches Symptom entstand erhöhter intrakranieller Druck.

In den drei nächsten Fällen besaß die Vergiftung einen kollektiven Charakter und war durch den Respirationstrakt zustande gekommen; zwei von den Vergifteten sind gestorben. Die Vergiftung trat infolge der Einatmung des Ethylfluids, das als Farblösungsmittel benutzt worden war, auf. Im klinischen Bild dominierten die Gehirnstörungen.

In allen tödlichen Fällen dieser Bleitetraäthylvergiftung wiesen die Obduktionsbefunde eine Schädigung der Capillaren des zentralen Nervensystems und eine Leberentartung auf. Es wurden auch Herzmuskel- und Nierenschädigungen festgestellt.

Die Lokalisierung und die Intensität der histologischen Veränderungen der inneren Organe stimmte im wesentlichen mit der in diesen Organen festgestellten Bleitetraäthylkonzentration überein.

Schlüsselwörter: Bleitetraäthyl — Gehirnstörungen — Schäden der Parenchymorgane.

Tetraethyllead (TEL) poisonings occur most often during the production of the substance, by its addition to gasoline, and by careless use of

it as a solvent. In comparison, poisonings resulting from intentional or unintentional ingestion of TEL are truly rare.

The clinical course of four cases of poisoning with tetraethyllead are presented. Three of the patients died as a result of the accident. The morphological and histochemical findings of these cases are also presented.

Clinical Observations¹

Poisoning by Ingestion

Case I. T. K., a 32 year old male with a defective sense of smell (caused presumably by an injury to the skull suffered several years before), swallowed approx. 3 spoonfuls of ethyl fluid by mistake. Immediately afterwards he drank a large quantity of water and vomited profusely. Two hours later he was admitted to the Clinical Department for Occupational Diseases.

At the time of admission the patient was conscious. He complained of headache, drowsiness and epigastric pain, and continued to vomit a reddish colored liquid. The conjunctivae of both eyes were congested. The oral cavity emitted an aromatic odor. The patient was apathetic but showed signs of motor excitement when vomiting. His blood pressure was 90/60 mm Hg; pulse was 82/min, respirations 18/min, and temperature 36.5° C.

In spite of immediate administration of 1.0 gm of EDTA and stomach lavage with Antidotum Metallorum "Sauter", as well as intensive symptomatic treatment, the patient's condition underwent a gradual but continuous deterioration. The pupils became dilated and lost power of accommodation, the retinal vessels narrowed, tendon reflexes increased, and incontinence of excrements ensued.

Laboratory findings revealed a reduced plasma alkali reserve of 11 mEq/l and a prothrombin time (Quick) of 42 sec (control was 15 sec). Urine: Protein 0.528^g/₁₀₀, sugar 1.9%, and cylinders and erythrocytes were found in the sediment. Peripheral blood count: Hct. 60%, Hb 12.2 gm-%, RBC 5,200,000, color index 1.16, and WBC 10,400.

By the eighth hour after ingestion of the poison, the patient was approaching a state of coma. On the second day after admission, several episodes of beginning pulmonary edema were recorded. The pulse rate was 116—142/min, blood pressure 85/50—140/90 mm Hg, respirations 26 to 38/min, temperature 36.8—37.6° C. Meningeal irritation signs appeared and tendon reflexes became more accentuated. Examination of the muscles showed an elevated tone and presence of fasciculations. Muscle excitability increased to actual twitching in response to moderate touch stimuli.

¹ The results of chemical studies carried out in these cases were reported by BOLANOWSKA et al.: Arch. Toxikol. 22, 287 (1967).

A spinal tap performed at that time showed a turbid and sanguineous liquor under increased pressure. Laboratory examination of the CSF revealed a pleocytosis of 15,600 cells/mm³, protein 52.8 mm-%, sugar 156 mg-%, chloride 127 mEq/l, Pandy positive, and Nonne-Apelt positive. Immediately following the spinal tap, there was a slight decrease in muscle tone and the patient broke out in profuse sweating. Subsequently, there was a gradual decrease in the deep tendon reflexes ending in total areflexia. The patient died 34 hours after admission with terminal signs and symptoms of pulmonary edema.

Group Poisoning

Three persons, a married couple I.W. and J.W., together with a home decorator S.C. hired by them, used approx. 250 ml of an unknown "solvent" over a 3 day period for painting the floor of an apartment. The remaining solvent was later examined and identified to be ethyl fluid. The married couple continued to live in the apartment during the entire period.

The total exposure to the TEL differed among the parties involved: I.W. about 95 hours, J.W. 72, and S.C. approx. 27 hours. It is assumed that the main route of TEL absorption was through the respiratory tract, but absorption through the skin cannot be excluded.

On the fourth day, counting from the first day they began to paint their apartment, I.W. and J.W. developed symptoms of abdominal pain, diarrhea, and vomiting. They were both taken to the hospital where a diagnosis of alimentary intoxication was made. At about the same time, the third party, S.C. suffered only headaches, and did not seek out medical attention.

Case II. I.W., a 44 year old female, developed on the 11th day (as counted above) signs of mental derangement including motor excitability and total disorientation. At the psychiatric hospital where she was admitted, a diagnosis of an acute state of confusion attributable to alimentary intoxication was made. Thirty hours later she died with symptoms of acute circulatory insufficiency preceded by hyperthermia.

Case III. J.W., a 40 year old male, was taken to the clinical Department for Occupational Diseases on the 13th day. He exhibited signs of mental dysfunction consisting of depressed level of consciousness with psychomotor excitability, partial disorientation and amnesia, as well as ataxia. Laboratory studies revealed 76 µg/100 ml of ionic lead in the urine, and a plasma alkali reserve of 13 mEq/l.

On the next day the patient's excitement increased and he left the clinic against the physician's advice. That same day he was readmitted to a psychiatric hospital where a diagnosis of acute schizophrenia was made. He was given specific treatment including injections of EDTA, but died 10 days later.

Case IV. S.C., the decorator, a 55 year old male, was called into the Clinic for Occupational Diseases. He complained of anorexia and total insomnia. The latter persisted for over a week in spite of hypnotic drugs. The level of ionic lead in the

urine was 17.6 $\mu\text{g Pb}/100\text{ ml}$. The patient spent 14 days in the hospital and was discharged in good condition.

In the poisonings described above, the toxic substance was identified as ethyl fluid containing 59% TEL in the first case and 31% in the remaining three cases.

The following are the concentrations of lead compounds found in the biological fluids of the three cases of TEL poisoning, given in $\mu\text{g}/100\text{ ml}$ (a = triethyllead; b = total lead):

Fluid	I (T.K.)		III (J.W.)		IV (S.C.)	
	a	b	a	b	a	b
Blood	243.0 ^a	400.0 ^a	15.0	333.0	12.1	130.0
Urine	18.5 ^a	550.0 ^a	4.6	90.0	8.8	66.0
CSF	266.0 ^a	—	—	—	—	—

^a After EDTA treatment.

Pathomorphological and Histochemical Investigations

Postmortem examination was performed in three of the cases. Sections were taken from different regions of the brain, myocardium, spleen, liver, pancreas, stomach, intestinal wall, kidneys, and adrenal glands. These were fixed in ice cold BAKER's formalin-calcium and in absolute ethanol.

In Cases I (T.K.), II (I.W.), and III (J.W.), routine paraffine sections were stained with hemalum eosin for general morphology, and Mallory's phosphotungstic acid hematoxylin stain (PTAH) for connective tissue, muscle, fibrin and mitochondria (PEARSE, 1960; MCMANUS and MOWRY, 1960). Frozen sections of the liver and kidneys were stained with OilRedO for the presence of neutral lipids.

An additional set of sections were taken from the brain, myocardium, liver and kidneys in Case I (T.K.). These were cut on a freezing-microtome with a knife-cooling device, and were fixed in formalin-calcium. Histochemical tests were then carried out to determine the activity of the following enzymes: Succinate (SD), lactate (LD) and alphaglycerophosphate (GPD) dehydrogenase (THOMAS and PEARSE, 1961); alkaline (AlkP) and acid (AcP) phosphatase (PEARSE, 1960); and carboxyl (Est) esterase (Gomori, modified by SHNITKE and SELIGMAN, 1961). In addition, the activity of aminopeptidase (NACHLAS and SALIGMAN, according to PEARSE, 1960) using L-leucyl-beta-methoxynaphtylamide as substrate was studied in sections of kidney.

Case I (T.K.) was examined 7 hours post mortem. The following pathomorphological changes were found: Dilated heart ventricles, acute congestion of all internal organs but particularly of the CNS including meninges, pronounced edema of the brain and pia, pulmonary edema, fresh focal hemorrhages in the lungs, most frequent within the subpleural regions of the lower lobes, and separate hemorrhagic spots scattered throughout the gastric and duodenal mucosa. No autolytic alterations were noted.

The histopathological findings were as follows: Erythrorrhagia into the perivascular spaces of the striatum and pons Varoli (the latter within the region of the fundus of the IV ventricle), loss of cross-striation in the majority of the myo-

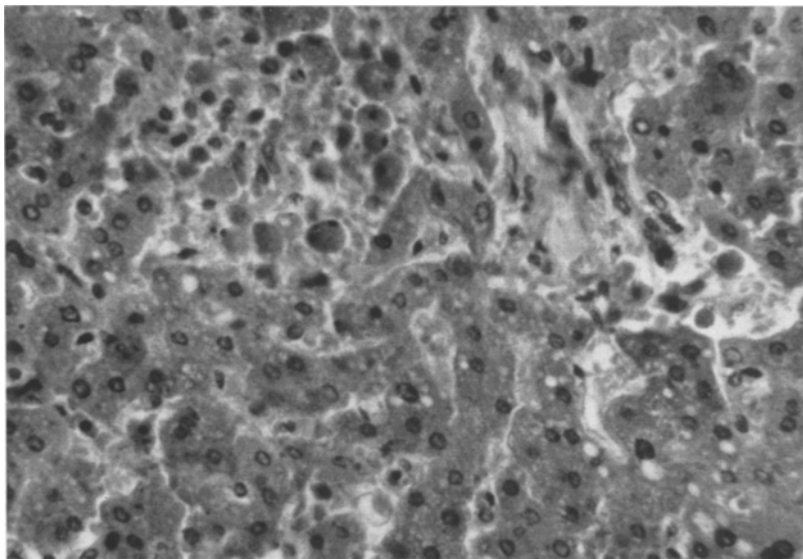


Fig. 1. Case I. Liver; parenchymal degeneration mostly of the hydropic type, an area of early necrosis in the upper left. H. E., $\times 300$

cardiac fibers and fragmentation of the same, a pronounced congestion of the liver with abundant amounts of protein-precipitate in the pericapillary spaces, and fatty degeneration of liver parenchyma predominantly involving cells near the periportal spaces in conjunction with a minimal degree of presumably beginning necrosis (Fig. 1). In the majority of the proximal renal tubule cells there was a loss of normal affinity to PTAH in the basal region of the cells (Fig. 2), and an abundant precipitate of protein within the lumen of the tubules and pericapillary spaces of the glomeruli.

All results of histochemical procedures carried out were significant except those for SD activity. Here there was presumably considerable post mortem and formalin inactivation of the enzyme. In the CNS, the activity of Est, AcP, LD and GPD in ganglion cell cytoplasm was essentially preserved although slightly depressed, whereas the test for AlkP in the capillary walls was almost entirely negative. LD and GPD activity in the myocardial fibers was greatly reduced. Liver parenchyma showed in numerous scattered areas a very low activity of all enzymes investigated. The cytoplasm of the parenchyma cells contained large granules, visible because of their strongly positive reaction to the test for AcP activity. These were especially large and numerous in the periportal regions (Fig. 3) and presumably represent enlarged lysosomes or large phagolysosomes. Distinct decreases in the LD, GPD and Est activity as well as decreased and diffusely distributed AlkP activity were observed in the proximal tubule cells of the kidneys. The reaction for AcP activity was weak in some but very strong in other segments of individual nephrons, where numerous large granular bodies similar to those in the liver parenchyma were observed. The distribution of LA activity was more uniform. It was most intense in the endothelium of the proximal convoluted tubules. AlkP activity in the walls of stromal capillaries was of a moderate and fairly uniform intensity.

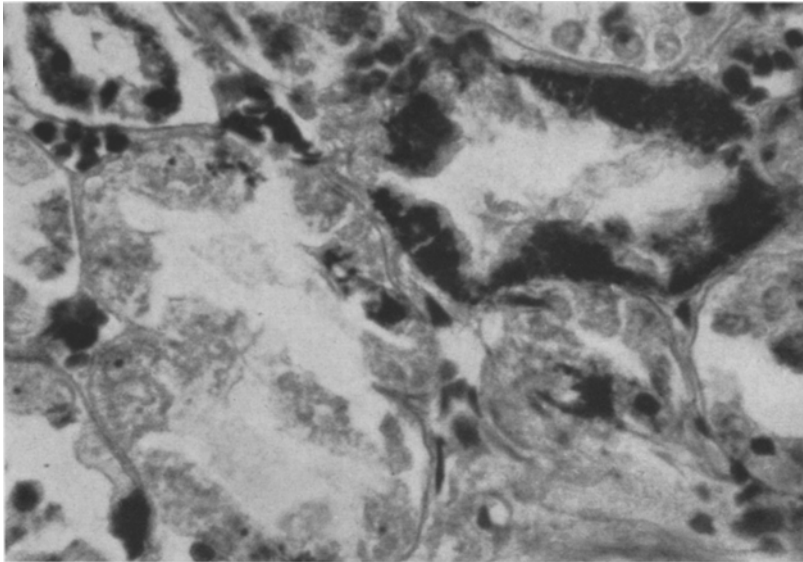


Fig.2. Case I. Kidney cortex, PTAH stained; loss of affinity to the stain in the epithelium of the convoluted tube (left) as compared to the partially preserved affinity in another one (upper right). $\times 500$

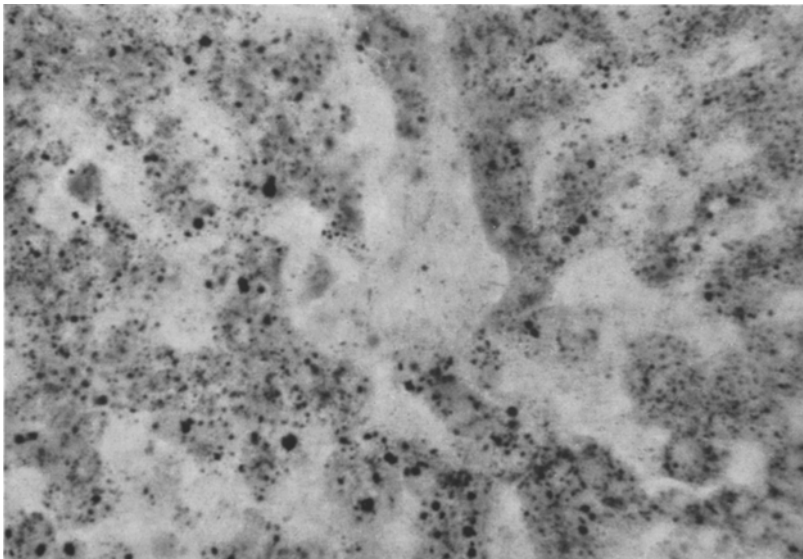


Fig. 3. Case I. Liver, a section after the test for acid phosphatase activity. Numerous enlarged bodies showing a strong positive reaction. $\times 300$

Three phenomena revealed by the histozymatic investigations in Case I deserve special attention: 1. Considerable reduction of AlkP activity in the cerebral capillaries lends additional proof of the abnormal permeability of these vessels; 2. the presence of enlarged cytoplasmic structures in hepatic and renal parenchyma showing high AcP activity and appearing similar to liver lysosomes, may be accepted as proof of injury, with the resulting partial desintegration of certain cell components; 3. the relatively large changes in enzymatic activity of the renal tubule cells indicates together with the changes revealed by PTAH staining an acute damage to the renal parenchyma.

In case II (I.W.), the autopsy was performed 82 hours after death. The following important morphological changes were recorded: Considerable congestion of all internal organs, especially of the brain, meninges, lungs and spleen; edema of the pia and brain; scattered foci of subendocardial hemorrhage and into the interventricular septum; degeneration of the liver; distinct signs of advanced putrefaction.

Case III (J.W.), which was examined 52 hours post mortem, revealed a high degree of congestion of the internal organs, edema of the brain and pia, pulmonary edema, and atherosclerotic foci in the coronary vessels.

The process of autolysis was sufficiently advanced in the last two cases, but especially in Case II (I.W.), to prevent precise delineation of subtle cytological changes. In both cases, however, the microscopic examination confirmed and supplemented the gross autopsy findings. Predominantly venous congestion and edema of the brain and lungs were found. Hemosiderin granules were detected in the macrophages present around the small vessels of the brain. Fatty degeneration of the liver was also observed. This was multifocal and limited almost exclusively to the cells of the periportal regions in both cases. Fatty degeneration of limited degree was also found within the renal cortex. In spite of autolytic changes, the affinity of the cytoplasm of the basal region of renal tubule cells to PTAH stain was only slightly reduced. PTAH stained myocardium clearly gave evidence of extensive fragmentation, yet cross striation was preserved, particularly in Case II (I.W.).

Discussion

The clinical course in the above described cases of serious poisoning varied somewhat, presumably because of differences in the amount of TEL ingested and the different routes by which it was absorbed.

In the case of accidental oral ingestion of the substance, distinct clinical symptoms developed remarkably fast, within minutes, while in the group poisoning there was a latent period of three days. The first symptoms to appear were gastrointestinal disturbances which preceded yet partially overlapped with the subsequent period of mental disorder.

In all of our cases, injury to the central nervous system was evident, as manifested by the following signs and symptoms: Insomnia, hyperthermia, signs of increased intracranial pressure and acute mental disorder

An acute state of confusion and acute episode of schizophrenia were the most striking mental disorders observed in the group poisoning. Acute psychoses simulating manic or acute schizophrenic syndromes are said to occur rarely in TEL poisonings [5]. In all ten of the cases reported

by ŁĘCKA (1951) [5], the mental disorder took instead the form of a toxic delirium.

Hyperthermia in acute TEL poisoning has been observed by CORSI and PICOTTI (1967) [2]. Injury to the CNS in tetraethyllead poisoning is attributed mainly to the action of triethyllead, a major metabolite of TEL. It has been shown experimentally by CREMER (1959) [3] that the degree of disruption in the glucose metabolism of the brain is directly proportional to the local triethyllead concentration. According to MAGISTRETTI et al. (1961) [6], the monoxidase in the brain is inhibited by the presence of TEL. This would imply that the symptoms of simultaneous neurological and mental disturbances are to be explained by an accumulation of serotonin within the CNS.

Defective oxidation of glucose manifests itself here clinically as a metabolic acidosis.

Certain of our observations may prove of importance in further elucidating the mechanism of brain injury as caused by triethyllead. In Case I (the oral poisoning), the concentration of triethyllead in the peripheral blood and in the CSF was 243.0 and 266 $\mu\text{g}\%$ respectively. The above figures make clear the fact that this highly toxic metabolite of TEL passes through the blood-brain barrier with comparative ease. This phenomenon is accompanied by an increase in the permeability of brain vessels with a tendency towards erythrorrhagia, as was observed in all our cases but most strikingly in the case of oral poisoning.

Injury to the liver in the form of fatty degeneration of the central zone of hepatic acini (peripheral area of the lobulus) was present in all our cases, in spite of the different doses and different routes of absorption of TEL. The kidneys and myocardium were the two organs most affected in the patients who died from oral poisoning, as was brought out most clearly in the histoenzymatic studies.

Our observations indicate a correlation between the distribution and intensity of the microscopic changes in internal organs and the triethyllead concentration in these organs as recorded by BOLANAWSKA and her co-workers [1]. Histopathological changes of a similar character and distribution were also found in dogs and rats exposed to TEL under experimental conditions [4].

References

1. BOLANAWSKA W., J. PIOTROWSKI, and H. GARCZYŃSKI: Triethyllead in the biological material in cases of acute tetraethyllead poisoning. *Arch. Toxikol.* **22**, 278 (1967).
2. CORSI G. C., e G. PICOTTI: Analisi clinice su une casistica di intossicati da piombo tetraetile. *Folia med. (Napoli)* **48**, 856 (1965).

3. CREMER, J. E.: Biochemical studies on the toxicity of tetraethyllead and other organo-lead compounds. *Brit. J. industr. Med.* **16**, 191 (1959).
4. DAVIS, R. K., A. W. HORTON, W. E. LARSON, and K. L. STEMMER: Inhalation of tetraethyllead and tetramethyllead. *Arch. environm. Hlth* **6**, 473 (1963).
5. ATECKA, H.: Exogenous psychoses in the course of tetraethyllead poisoning. [Polish] Warszawa: PZWL 1951.
6. MAGISTRETTI, M., M. PEIRONE e A. MAJONI: Azione in vitro del piombo-tetraetile sulla monoaminossidasi cerebrale. *Med. d. Lavoro* **52**, 498 (1961).
7. STRAUS, W.: Lysosomes, phagosomes and related particles. In: *Enzyme cytology* (D. B. Roodyn, editor), p. 239. London: Acad. Press 1967.

Dr. M. STASIK
Institute of Occupational Medicine
in the Textile and Chemical Industries
Teresy 8
Łódź 11 (Poland)